

## **Anatomical and histological studies on the male reproductive system of the red swamp crayfish *Procambarus clarkii*.**

**Abd El-Halim A. Saad and Montaser M. S. Hassan.**

Zoology Department, Faculty of Sci., Ain Shams Univ., Cairo, Egypt.

### **ABSTRACT**

The male reproductive system of *Procambarus clarkii* consists of two milky white testes; each one consists of anterior and posterior portions. The two testes are separated anteriorly and united posteriorly. A collecting duct arises from each testis. These ducts meet together at the middle point between the anterior and posterior testes, from this point; a long coiled, thread-like vas deferens extends. It is tubular and white in colour. The right one is longer, thicker and coiled, while the left one is shorter transparent and not coiled. Both the left and right vasa deferentia extend posteriorly to open with the male gonopore on the last thoracic appendages. Histologically, the testis consists of acini in which stages of spermatogenesis occur. Spermatides pass to the collecting tubules, where they become mature sperm and packed in a spermatophore in the vas deferens. The wall of the collecting tubules consists of simple cuboidal cells. The vas deferens is divided into two regions; the glandular and ejaculatory regions. The first is lined with secretory columnar epithelium, while the second has a muscular wall of longitudinal and circular muscles and lined with single layer of ciliated columnar epithelium.

**Key words:** anatomy, histology, male reproductive system, *Procambarus clarkii*

### **INTRODUCTION**

The freshwater crayfish, *Procambarus clarkii* (Girard, 1852) had invaded most of the governorates in Egypt. Its distribution has extended from Northern Delta to Assuit (Saad & Emam, 1998). It had been successfully introduced to west India, Europe, the Middle East, eastern Asia and Africa *i.e.* it invaded various habitats (Huner, 1992). This invader has an amphibious mode of life, it can live out of water for long times because it can utilize the atmospheric oxygen as its gills are moistened with water. This animal can withstand the life in shallow water and it is highly adaptable and resistant for severe unfavorable conditions due to its hard exoskeleton. Moreover, it burrows deep tunnels in the banks of irrigation canals, helping it to survive drastic seasonal fluctuations. *P. clarkii* is a polytrophic or omnivorous animal *i.e.* it is not fastidious to any kind of food. It was found that this crayfish feeds on fragile snails which act as intermediate hosts for some important diseases (Ibrahim *et al.*, 1995).

Moreover, Ibrahim *et al.* (1997) and Soliman *et al.* (1998b) investigated the habitat and behavior of the red swamp crayfish. Soliman *et al.* (1998a)

examined the reproductive biology of the animal. Additionally, Saad and Emam (1998), Shakir and Ibrahim (1998) and Mubarak (2001) studied the distribution of the crayfish in Egypt. Aly (2000) examined the pathological effects of Jojoba seed oil and fenthion (organophosphorus) insecticides on the ovary, digestive gland and muscles of the *P. clarkii*. Sharshar and Geasa (1998) examined the effect of copper on the hemocytes of *P. clarkii* which caused destruction and change of their ratio. Tolba (1999) used the crayfish *P. clarkii* as a biological indicator for water contamination with copper and cadmium. He found that the respiration rate increases as the pollutants increase. Sleem and El-Hommosany (2008) studied its behavior and ability to control schistosomiasis in Egypt.

Although the crayfish is widely distributed in the Egyptian freshwater systems, there is a little information about this species (IAA, 1995). Therefore, the present work was designed to study the anatomical and histological structure of the reproductive systems of the crayfish *P. clarkia*, which considered one of the strongest factors influencing his survival and resistance to the environmental conditions. Most of the previous studies on the crayfish were focused on the ecological, physiological and aquaculture. However, the anatomical and histological studies were not so integrated to give complete information about this animal especially the reproductive system.

### MATERIAL AND METHODS

Specimens of *P. clarkii* were collected from the irrigation canals from EL-Kanater El-Khayreya; 20 Km North of Cairo using gobia baited with fishes. These animals were taken alive in wide container to the laboratory. They were placed in glass aquaria 20 x 25 x 30 cm that were filled with dechlorinated tap water which was aerated by air pumps. The water was continuously changed every two days. They were fed on lettuce leaves and formulated diets. Only fully grown animals of 10-12 cm total length were used.

For the anatomical studies, alive males were dissected in the laboratory without using any anesthetic drugs. The reproductive system was removed away, placed in 0.6 % saline solution and were drown by using dissecting microscope provided with camera lucida.

Other specimens were dissected for the histological and histochemical studies. The testes, vas deferens were placed directly into the appropriate fixative. Aqueous and alcoholic Bouin and 10 % formaline solutions were used for 24 hours. After fixation the tissues were dehydrated using ascending series of ethyl alcohol, cleared in terpeneol and embedded in paraplast. Serial sections were cut at 5  $\mu$ m thickness. The sections were deparaffinized, hydrated and stained by various stains.

Staining solutions were Mayer's hematoxylin counterstained with eosin (HX&E), periodic acid Schiff (PAS) for general carbohydrates and mercury bromophenole blue for general protein. The slides were cleared in xylene and mounted in DPX.

## RESULTS

The *P. clarkii* is dioecious crustacean animal. Externally there are many differences between male and female; *i.e.* sexual dimorphism. This appears in the enlargement of the first pair of chelipeds in males than that of females. The first and second abdominal appendages in the male are rigid, rod-shaped and modified to form tubular copulatory organ (Fig.1) for transferring the spermatophores from male gonopore to the female.

### 1- Anatomy of the male reproductive system:

The reproductive system of the male is found in the thoracic cavity above the digestive gland and just beneath the pericardial sinus. The male reproductive system is formed of two milky white testes (Figs. 2 & 3) each one consists of anterior and posterior portion (t.). They are separated anteriorly and fused posteriorly. A collecting duct (c.d.) arises from each testis. These ducts meet together at the middle point between the anterior and posterior testis, from this point; arises a long coiled thread-like vas deferens. It is tubular and white in colour. The right vas deferens (r.v.d.) measures about 44 mm in length and its diameter is about 400  $\mu$ m at the anterior end and 750  $\mu$ m at the posterior end. The left vas deferens is 24 mm in length and 280-290  $\mu$ m in diameter in other words the right one is longer, thicker and coiled while the left one is shorter transparent and not coiled. Both the left and right vas deferens runs posteriorly to open with the male gonopore on the last thoracic appendages.

### 2-Histology of the reproductive system:

Histologically, the testis consists of numerous testicular acini (ac.) which are variable in size and shape. Each of them is surrounded by a basal lamina (b.l.) upon which the germinal epithelium rest. The stages of spermatogenesis are spermatogonia (spg.), primary spermatocytes (p.sp.) (Fig.4). Secondary spermatocytes (s.sp.) and spermatides (spt.) pass to the collecting tubules. Spermatozoa (spr.) pass to the vas deferens where they are packed together in tubular spermatophores in the vas deferens.

The spermatogonia originate from the mitotic division of the germinal epithelium. These cells appeared as a distinct darkly stained cells located at the periphery of the acinus wall (Fig. 4). They are small cells packed by a thin membrane which ruptures releasing these cells into the lumen of the acinus. The released cells enlarge in size giving the second stage, the primary spermatocyte.

The primary spermatocytes are larger than the spermatogonial cells which filled the lumen of the acinus. They have a central spherical large nucleus surrounded by a thin zone of non granulated cytoplasm. These cells divide meiotically giving rise the next stage, secondary spermatocytes. Figure (5) shows the metaphase of the cell division of the primary spermatocytes and the chromosomes at the equatorial plane of the cell.

The secondary spermatocytes are formed in large numbers and small in size having faintly stained cytoplasm around small spherical nucleus. As soon as

these cells are formed, they pass into the lumen of the collecting tubules (c.b.) where they divided mitotically giving the spermatides (Fig. 6). The spermatides are smaller in size than the secondary spermatocytes but larger in number. Each cell has a thin cytoplasmic zone around a spherical centrally located nucleus (Fig. 7).

The spermatozoa are non-motile. It has a central nucleus and above which is the acrosome; from the body of the sperm arise four arched processes or nuclear spikes (n.s.). They are stained with deep colour in hematoxylin-eosin stained preparations (Fig. 8). Each sperm has a central pale part which indicates the presence of the acrosome above the nucleus which gave a positive colouration with periodic acid Schiff reagent (PAS) (Fig. 9). The sperms are grouped in the vas deferens where they are encapsulated to form the spermatophore (Fig. 10). It is very small cylindrical rod shaped structure formed during its way from the testis to the distal portion of the vas deferens measuring 700  $\mu\text{m}$  in length and about than 200  $\mu\text{m}$  in diameter. The wall of the spermatophore is thick and formed of three layers outer vacuolated layer (v.l.), middle smooth layer (s.l.) and inner granulated layer (g.n.) (Fig. 11).

#### **The collecting tubules:-**

There are numerous branched collecting tubules (c.b.) arise from the acini (Fig. 7). They connected together at the lower part of the testis where they form main collecting duct. It originates at the base of the lobe of the testis and unite together to transfer the spermatides from the testicular acini to the collecting ducts and the vas deferens.

The collecting tubule has a wide circular lumen lined with single layer of cuboidal epithelial cells (c.c.) (Fig. 7). The cytoplasm is acidophilic and coarsely granulated. The nucleus is spherical located at the central part of the cell and has a large excentric nucleolus. Chromatin granules are found at the inner surface of the nuclear envelope. The lining epithelium rest on a basal lamina which is followed by unstrained circular muscle layer (c.m.).

#### **The vas deferens:-**

##### **A- The right vas deferens:-**

The histological structure of the right vas deferens revealed that it is distinctly divided into two regions; non-ciliated (glandular region) and ciliated (ejaculatory) regions. The inner wall of the non-ciliated or glandular region is lined with tall columnar epithelial cells (cl.c.) (Fig.12). The cytoplasm of these cells is finely granulated and acidophilic. Each cell has an oval nucleus (n.) located at the basal half of the cell with one excentric nucleolus and numerous coarse chromatin granules distributed throughout the nucleoplasm. There are darkly stained cylindrical, secretory cells (s.c.) between the columnar cells (Fig. 13). They react positively with bromophenol blue indicating their high protein contents (Fig. 14). A thin circular unstriated muscle layer (c.m.) follows the epithelial cells; the outer most layer is the longitudinal unstriated muscle layer.

The ciliated or ejaculatory region is short with a wide lumen (lu.). The lumen is lined with a single layer of ciliated short columnar epithelial cells (c.cl.c.). The epithelial lining of this region is folded into four small folds. The cytoplasm of these cells is finely granulated. Each cell has an oval nucleus near the base of the cell with one excentric nucleolus. The distal region has a thick muscular wall to ejaculate the spermatophore outside the vas deferens. It is formed of an inner thick longitudinal muscles (l.m.) and an outer circular muscle (c.m.). These muscles are striated (Fig. 15).

**B-The left vas deferens:-**

Histologically, the left vas deferens has a narrow lumen. It does not contain any spermatophores there is no ciliated region (Fig.16). Its lining epithelium consists of a single layer of columnar cells each with an oval basal nucleus. The cytoplasm is coarsely granulated. There is a coarse chromatin granules at the inner side of the nuclear envelope. A thin circular unstriated muscle layer surrounded the vas deferens.

### DISCUSSION

The male reproductive system of *P. clarkii* consists of two testes which are free anteriorely and unite together posteriorely forming one median lobe.

Histologically; the testis consists of numerous testicular acini. Each of them contains the different stages of spermatogenesis were developed. Fully mature sperms are packed together in tubular containers, spermatophores.

Borradail (1930) postulated that the testis of he crayfish *Astacus* consists of a number of branched ducts end in small alveoli, in which the spermatozoa are formed. These results do not agree with those in the present study because the testis consists of testicular acini and collecting tubules besides, the mature spermatozoa are not formed in the acini. Dudenhausen and Talbot (1983) and Mubarak (2001) reported that the male organs of the *P. clarkii* are white consisting of two testes and two vasa deferentia. The testis consists of two anterior lobes and a median posterior one.

Hussein and Obuid-allah (1992) observed that the male reproductive organs of the shrimp *Cardina nilotica* are gray in colour, united anteriorely but become separated posteriorely. These findings do not agree with those in the present investigation. Similar result was discussed on the testis of *Thenous orientalis* by Burton (1995). The same author declared that the spermatogonia are distinct cell mass located adjacent to the acinus wall. Heiba (1998) and Mubarak (2001) supported these results.

In the present study, the primary spermatocytes fill the space of the acinus. At the end of the meiosis, secondary spermatocytes pass from the acinus into the collecting tubule where they are transformed to spermatides. These observations were supported by Burton (1995) in the testis of *Thenous orientalis*.

The spermatozoa of the present crayfish *P. clarkii* are non-motile. It has a central nucleus and above which is the acrosome; from the body arise four spikes. Borradail (1930) pointed that the spermatozoa of the crayfish *Astacus* sp. are discoid with stiff pointed processes around the edge. However, Borradail *et al.* (1963) reported that the sperm of *Astacus fluviatilis* has a complex unusual structure and they are immobile. Talbot and Summers (1978) defined these spikes as nuclear spikes in the *Panulirus* sp. However, Dudenhausen and Talbot (1983) studied the sperm of the crayfish *Pacifastacus leniusculus* and they found that the sperm has about 15-20 nuclear spike. Also Kershaw (1994) described the sperm of *Astacus* sp. that it has a star-shaped structure provided with numerous tangential spines. Burton (1995) indicated that the spermatides of *T. orientalis* become encapsulated by a colourless spermatophores or sperm capsule which is secreted by the glandular region of the vas deferens. Moreover, the previous author stated that mature sperm of the lobster *Thenous orientalis* is pyramidal in shape and consists of three regions; the acrosome, the cytoplasmic matrix and the nucleus. Three pairs of nuclear filaments radiate from the sperm. Unlikely, Heiba (1998) noticed that the sperm of the *P. clarkii* as an elongated structure. Mubarak (2001) reported that the spermatozoon of the *P. clarkii* has four arms and are found in the vasa deferentia. Furthermore, Talbot and Summers (1978) described that decapod crustacean sperm consists of a spherical body and spike which radiate from this body. They stated that in some species the acrosome is elongated and form a prominent projection from the sphere as in *Homarus*. The same authors found that the number of spikes are variable according to the species. In reptantians (crayfish, lobsters and crabs) multiple spikes project from the nucleus; while in natantians (shrimp) a single spike originate from the acrosomal region. The spike are extension of the nucleus and are limited internally by the nuclear membrane. The chromatin is continuous with the lumen of the spike. They found that reptantian sperm spikes contain microtubules arranged in 2 + 9 axonime characteristic of typical flagellated sperm but the spikes are stationary and the sperm are immotile. These results support the present observations where the sperm of *P. clarkii* fit the same plane of reptantian sperm. On the other side, Beach and Talbot (1987) studied the sperm of the *Cherax tenuimanus* and *Cherax albidus*. Newly extruded eggs are pushed along the ventral surface thus fertilization occurs as the egg passes over the stationary sperm. The acrosome of sperm of *C. tenuimanus* is strongly PAS positive. These observation agrees with the present work since all sperms in *P. clarkii* are stationary and positively stained after PAS.

The spermatophore of the *P. clarkii* is small in size. Its wall consists of three layers, granular, homogeneous and vacuolated. Dudenhausen and Talbot (1983) reported that the spermatophores are small, cylindrical structure measuring 4-9 mm in length and less than 1 mm diameter. It consists of a central sperm mass embedded within dense matrix surrounded by the spermatophore wall. The spermatophore is assembled during transit from the testis to the distal

vas deferens. However, Kooda-Cisco and Talbot (1982) found that the spermatophore of the lobster *Homarus americanus* measure 1-2 cm in length and 0.5-1 cm diameter. It is comprised of sperm mass surrounded by three acellular layers, primary spermatophore, intermediate and outer bounding layers. The first is homogeneous layer surrounding the sperm mass. The second contains granules. The third one contains filaments and fibers giving it the fluffy appearance. In most macrurans (crayfish, lobsters) form a continuous cordlike (tubular or non-pedunculate spermatophores).

There are two long thread-like vasa deferentia in the crayfish *P. clarkii*. They are tubular and white in colour. The right one is longer, thicker and coiled while the left one is shorter transparent and not coiled. Both the left and right vasa deferentia run posteriorly to open with the male gonopore on each side. The right one is divided into non ciliated and ciliated regions

Borradail (1930) reported that the vasa deferentia of *Astacus* are narrow and coiled; their anterior parts are narrow and translucent, the second part which forms most of the duct is wider and glandular. The terminal region has a muscular wall which forces the sperm to outside. Furthermore, Talbot and Summers (1978) declared that there are three regions in the vas deferens of the spiny lobster *Panulirus*; the proximal, glandular and the muscular or ejaculatory segments. All the above results are compatible with those in the present study.

However, Burton (1995) stated that the vas deferens of the lobster *Thenous orientalis* is divided into three regions; proximal, medial and distal parts. These results matches the present observations since there are no sperms were observed in the acini but in the spermatophore in the vas deferens and the musculature of the vas deferens increase the distal end. This observation agrees with those in the present work where the non ciliated region of *P. clarkii* corresponds to the glandular part while the ciliated one is the muscular part. However, Dudenhausen and Talbot (1989) found that the vasa deferentia of *P. clarkii* are long convoluted tubes. Huner and Barr (1991) indicated that the left vas deferens of male crayfish *P. clarkii* is reduced and non-functional. This finding comes in a great compatibility with the present work where the left vas deferens is thin transparent, uncoiled and does not contain any sperm. Hussein and Obuid-allah (1992) indicated that there are two vasa deferentia in the shrimp *Cardina nilotica* extending vertically downwards, each vas deferens ends with wollen vesicula seminalis. These do not agree with the present study.

#### REFERENCES

- Aly, R.H. (2000). Effect of natural and chemical insecticides on some organs of the female crayfish *Procambarus clarkii* (Crustacea: Decapoda) from the River Nile, Egypt. *Egypt. J. Aquat. Biol. Fish.*, 4(4): 83-103.
- Beach, D. and Talbot, P. (1987). Ultrastructural composition of sperm from the crayfishes *Cherax tenuimanus* and *Cherax albidus*. *J. Crust. Biol.*, 7(2): 205-18.

- Beams, H.W. and Kessel, R.G. (1963). Electron microscope studies on developing crayfish oocytes with special reference to the origin of yolk. *J. Cell. Biol.*, 18, 621-64.
- Booolootina, R.A. and Heyneman, D. (1962). An illustrated laboratory text in zoology.
- Borradaile, L.A. (1930). *Elementary Zoology for medical students*. Second edn. Cambridge at the Univ. Press.
- Borradaile, L.A., Potts, F.A., Eastham, J.T. and Kerkut, G.A. (1963). *The invertebrata, a manual for the use of students*. Cambridge at the Univ. Press. pp. 354-367.
- Burton, T.E. (1995). The spermatid pathway and associated reproductive structure of the squat lobster *Thenus orientalis* (Lund, 1793). *Invert. Reprod. and develop.*, 28(1): 53-61.
- Dudenhause, E.E. and Talbot, P. (1983). An ultrastructural composition of soft and hardened spermatophores from the crayfish *Pacifastacus leniusculus* Dana. *Canad. J. Zool.*, 61 (1): 182-94.
- El-Sherif, S.S. (1987). A scanning electron microscopic study on the egg of *Portunus pelagicus* (L.). *Proc. Zool. Soc. A. R. Egypt*. 14: 24-32.
- Gherardi, F. and Barbaresi, S. (2000). Invasive crayfish: activity patterns of *Procambarus clarkii* in the rice fields of the Lower Guadalquivir (Spain). *Arch Hydrobiol.*, 150: 153-68.
- Habashy, M.M. (2004a). Survival and growth rates of *Procambarus clarkii* (Girard) (Crustacea- Decapoda) under different temperature and salinity levels. *J. Egypt. Ger. Soc. Zoology*, 34(D): 135-46.
- Habashy, M.M. (2004b). Effect of some artificial and natural diets on the growth rate of red swamp crayfish, *Procambarus clarkii* under laboratory conditions. *Egypt. J. Aquat. Biol. Fish.*, 8(1): 225-41.
- Hashem, H.O., Abdel Hamid, N.F. and El-Sawi, N.M. (1991). Histological studies on the ovaries of *Panoeus kerathurus* (Leach) after deprivation of the eyestalk hormones. *J. Egypt. Ger. Soc. Zool.* 5: 137-51.
- Heiba, F.N. (1998). Effects of  $\gamma$ -irradiation on the gametogenesis of the freshwater crayfish *Procambarus clarkii* (Girard, 1852). *Egypt. J. Aquat. Biol. Fish.*, 2(4): 29-45.
- Hilmy, A.M.H., El-Zayat, M.A., Adham, K.H.G. and Abdel Hamid, N.F. (1989). Metabolic activities of the hepatopancreas of the crab *Portunus pelagicus* (Linnaeus) after eyestalk ablation. *Egypt. J. Histol.*, 9 (2): 329-37.
- Huner, J.V. and Barr, Z.E. (1991). *Red swamp crawfish biology and exploitation.*, Third edn. Louisiana Sea Grant College Program Center for wetland Resources Louisiana State University Baton Rouge, Louisiana. pp.4-26.

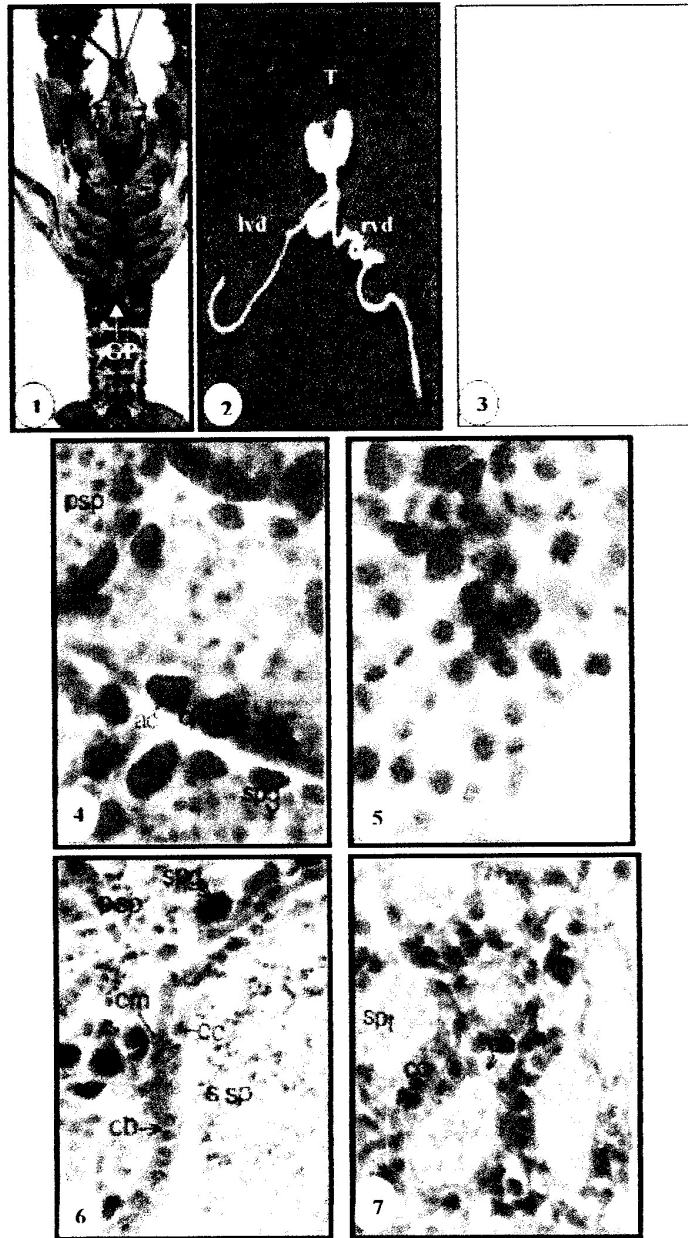


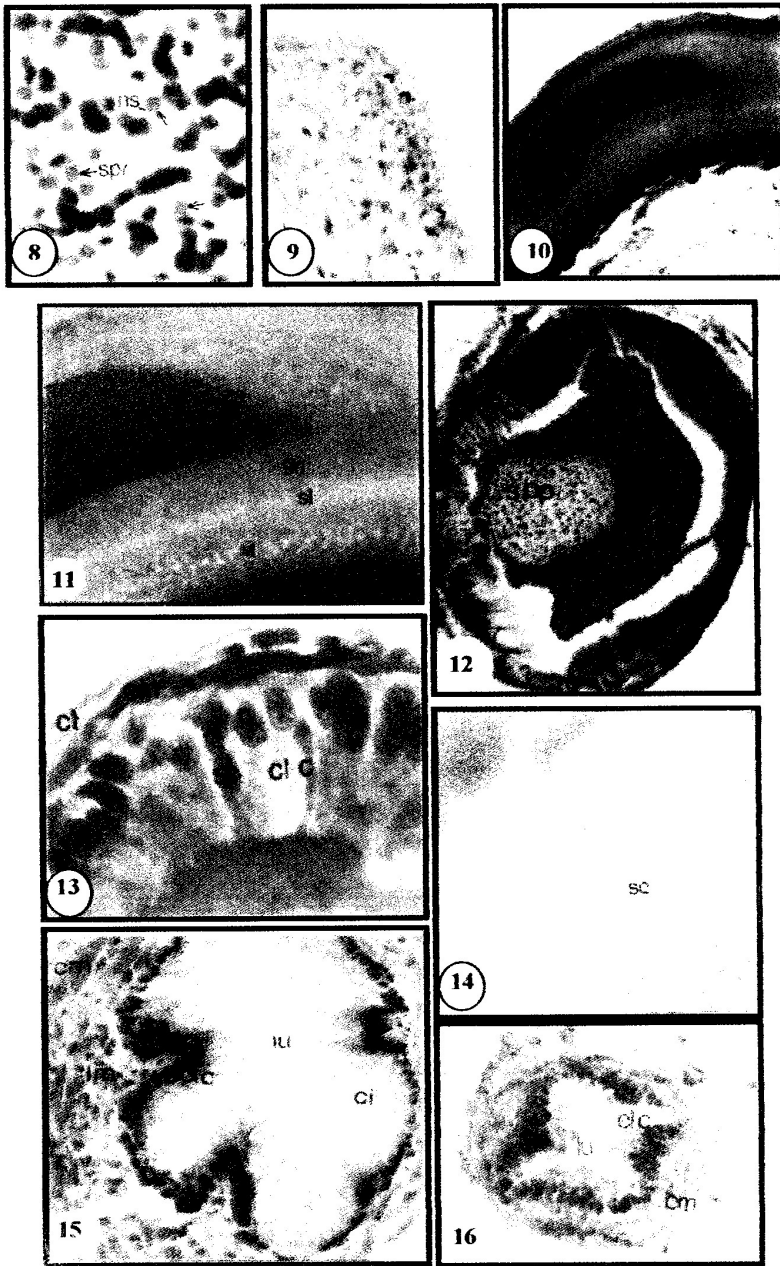
- Hussein, M.A. and Obuid-allah, A.H. (1992). Anatomical studies on the reproductive and digestive systems of the freshwater prawn *Caridina nilotica* collected from Egypt. *J. Egypt. Ger. Soc. Zool.*, 9(D): 53-71.
- IAA, (1995). International Association of Astacology News letter pp.15
- Ibrahim, A.M., Emam, W.M., Mubarak, F.M., Beltagy, S.M. and Tharwat, A.A. (2006). On the reproductive biology of the crayfish *Procambarus clarkii* in Egypt. *J. Egypt. Acad. Soc. Environ. Develop.*, (D)7(1): 145- 71.
- Ibrahim, A.M., Khalil, M.T. and Mubark, M.F. (1997). Ecological studies on the exotic crayfishes *Procambarus clarkii* (Girard, 1852) and *Procambarus zonangulus* (Hobbs and Hobbs, 1990), in the River Nile. *Int. J. Ecol. & Env. Sci.*, 23: 217-28.
- Ibrahirn, A.M., Emam, W.M., Beltagy, S.M., Tharwat, A.A. and Mubarak, F.M. (2000). On some factors affecting molting of the crayfish *Procambarus clarkii* from the River Nile, Egypt. *J. Environ. Sci.*, 1(1): 23-45.
- Kershaw, D.R. (1994). *Animal diversity.*, First. edn. Chapman and Hall, London. pp. 123-130.
- Kooda-Cisco, M.J. and Talbot, R. (1982). A structural analysis of the freshly extruded spermatophore from the lobster, *Homorus americanus*. *J. Morphol.*, 172: 193-207.
- Kulkarini, G.K., Glade, L. and Fingerman, M. (1991). Oogenesis and effects of neuroendocrine tissues on in vitro synthesis of protein by their ovary of the red swamp crayfish *Procambarus clarkii* (Girard). *J. Crust. Biol.*, 11(4): 513-22.
- Marshall, A. Z. and Williams, W.D. (1975). *Textbook of Zoology (Invertebrates).*, 7th edn. GLBS and Macmillan, 1: 507-508.
- McRae, T.G. and Michell, B.D. (1995). Studies on ovarian development in the Yabby, *Cherax albidus* (clark). *Fresh. Crayf.*, 10: 521-31.
- Medina, A., Vila, Y., Mourente, G. and Rodriguez, A. (1996). A comparative study of the ovarian development in wild and pond-reared shrimp, *Panaeus kerathurus* (Forsk., 1775). *Aquacult.*, 148: 63-75.
- Mubarak, F.M. (2001). Fishery management of the exotic crayfish *Procambarus clarkii* in the irrigation canal of the River Nile, Egypt. Ph.D. Thesis, Institute of Environ. Study and Research, Ain Shams Univ., Cairo, Egypt.
- Raafat, H.A. (2006). Biological and physiological studies on the freshwater crayfish, *Procambarus clarkii* Ph. D. Thesis, Department of Zoology, Girls College for Arts, Science and Education, Ain Shams University, pp. 267.

- Ramalho, R.O., Correia, A.M. and Anastacio, P.M. (2008). Effects of density on growth and survival of juvenile Red swamp crayfish *Procambarus clarkii* reared under laboratory conditions. *Aquacult., Res.*, 39(6): 577-86.
- Saad, A.A. and Emam, W.M. (1998). Field and semifield studies on the crayfish *Procambarus clarkii* in Egypt. *Egypt. J. Aquat. Biol. Fish.*, 2 (4): 331-44.
- Sagi, A., Snir, E. and Khalila, I. (1997). Sexual differentiation in decapod crustaceans: role of the androgenic gland. *Invert. Reprod. Develop.*, 31(1-3): 55-61.
- Shakir, S.H. and Ibrahim, A.M. (1998). Population dynamics and distribution of the newly introduced crayfish *Procambarus clarkii* in Egypt using geographic Introduction System (GIS). *Egypt. J. Aquat. Biol. Fish.*, 2 (4): 537-51.
- Sharshar, K.M. and Geasa, N.M.S. (1998). Effect of Copper on hemocytes in the crayfish, *Procambarus clarkii* (Crustacea, Decapoda). *Egypt. J. Aquat. Fish.*, 2 (4): 1-13.
- Soliman, G.N., El-Assal, F., Salah El-Deen, M. and Hamdy, S.A.H. (1998a). The reproductive biology of the red swamp crayfish *Procambarus clarkii* (Girard, 1852) (Decapoda: Cambaridae) in the River Nile, Egypt. *Egypt. J. Zool.*, 30: 311-25.
- Soliman, G.N., El-Assal, F., Salah El-Deen, M. and Hamdy, S.A.H. (1998b). Habitat, distribution and behaviour of the red swamp crayfish *Procambarus clarkii* (Girard, 1852) (Decapoda: Cambaridae) in the River Nile, Egypt. *Egypt. J. Zool.*, 30: 297-310.
- Stephens, G.J. (1952). Mechanisms regulating the reproductive cycle in the crayfish, *Cambarus* The female cycle *Physiol. Zool.*, 25(1): 70-86.
- Talbot, P. (1981). The ovary of the lobster, *Homarus americanus*. II Structure of the mature follicle and origin of the chorion *J. Ultrastruc. Res.*, 76: 249-62.
- Talbot, P. and Summers, R.G. (1978). The structure of sperm from *Panulirus*, the spiny lobster, with special regard to the acrosome. *J. Ultrastruc. Res.*, 64:341-51.
- Tero, A. (2007). Food intake, growth and social interactions of signal crayfish, *Pacifastacus leniusculus* (Dana). M. Sc.Thesis, Faculty of Bioscience, University of Helsinki for public criticism in Auditorium. Korona Information Cent., Helsinki, pp.60.
- Tolba, M.R. (1999). The red swamp crayfish *Procambarus clarkii* (Decapoda: Cambaridae) as bio-indicator for total water quality including Cu and Cd pollution. *Egypt. J. Aquat. Biol. Fish.*, 3(1): 59-71.

### EXPLANATION OF FIGURES

- Fig. 1:-Photograph of ventral view of male crayfish showing gonopods (gp.) and gonopore (gr) on the 8<sup>th</sup>. thoracic appendages.
- Fig. 2:-photograph of the male reproductive system showing the trilobed testis (t.), left vas deferens (l.v.d.) and the right vas deferens (r.v.d.).
- Fig. 3:-Camera lucida drawing of the male reproductive system of *P. clarkii* showing the testis (t.), left vas deferens (l.v.d.) and the right vas deferens (r.v.d.) and collecting duct (c.d.).
- Fig. 4:-Photomicrograph of T.S. of the testis showing the testicular acini (a.c.), spermatogonia (spg.), primary spermatocytes (p.sp.) and basal lamina (b.l.) [Bouin, HX&E (650X)].
- Fig. 5:-Photomicrograph of part of T.S. of testis showing the metaphase (mp) of the meiotic division of the primary spermatocyte [Bouin, HX&E (650X)].
- Fig. 6:-Photomicrograph of part of T.S. of testis showing the primary spermatocytes (p.sp.), secondary spermatocytes (s.sp.) within the collecting tubule (c.b.) circular muscles (c.m.) and the cuboidal cells (c.c.) of this duct [Bouin, HX&E (422X)].
- Fig. 7:-Photomicrograph of T.S. of the testis at the lower part showing the collecting tubules (c.b.) containing spermatides (spt.), the cuboidal cells (c.c) [Bouin, HX&E (422)].
- Fig. 8:-Photomicrograph of mature sperms (spr.) from the spermatophore showing the nuclear spines (n.s.) [Bouin HX&E. (1660X)].
- Fig. 9:-Photomicrograph of mature sperm showing the positive reaction of the acrosome to the carbohydrate contents (acr.) [Alcoholic Bouin, PAS. (650X)].
- Fig. 10:-Photomicrograph of L.S. of the right vas deferens showing the spermatophore (spp.). [ Bouin, HX&E (160X)].
- Fig. 11:-Photomicrograph of L.S. of the right vas deferens showing the wall of the spermatophore consisting of three layers; the vacuolated layers (v.l), smooth layer (s.l.) and granular layer (g.). [ Bouin, HX&E (422X)].
- Fig. 12:- Photomicrograph of T.S. of the right vas deferens at the non-ciliated region showing the wide lumen, and spermatophore (spp.) at the center. [Bouin, HX&E (160X)].
- Fig. 13:-Photomicrograph of part of T.S. of the right vas deferens at the non-ciliated region showing, columnar cells (cl.c.), secretory cells (s.c.), circular muscular layer (c.m.) and connective tissue (ct.). [Bouin HX&E (422X)].
- Fig. 14:-Photomicrograph of part of the glandular (median) part of the vas deferens showing the positive reaction of the secretory cells (s.c.) to the protein stain. [10% Formalin. Bromophenol Blue (650X)].
- Fig. 15:- Photomicrograph of T.S. of the right vas deferens at the ciliated region showing the ciliated columnar cells (c.cl.c.) and long tufts of cilia (ci.), and the thick muscular wall [Bouin, HX&E.(160X)].
- Fig. 16:-Photomicrograph of the left vas deferens showing its reduced lumen (lu.) columnar cells (cl.c.) circular muscle layer (c.m.). [Bouin, HX&E (160X)].





دراسات تشريحية وهستولوجية على الجهاز التناسلي الذكري لروبيان المستنقع الأحمر  
بروكامبارس كلاركى.

عبد الحليم عبد سعد - منتصر محمد حسن  
قسم علم الحيوان- كلية العلوم- جامعة عين شمس - القاهرة - مصر.

أوضحت الدراسة التشريحية ان الجهاز التناسلي الذكري لروبيان المستنقع الأحمر بروكامبارس كلاركى يتكون من خصيتين بيض اللون؛ كل واحدة تتكون من جزء أمامي واخر لخفي. تظل الخصيتين حرتين من الأمام بينما تتحدان من الخلف مكونة منسل على شكل حرف Y. يرتبط الجزء أن الأماميان و الجزء الخلفي بمجموعة من الأنبيبات المجمع. وتلتقي هذه الأنبيبات معا في نقطة بين الجزء الأمامي والخلفي ويمتد من هذه النقطة وعاء ناقل على كلا الجانبين. والوعاء الناقل الايمن أبيض طويل و ملتف بينما الايسر هو أقصر وشفاف وغير ملفوف ويمتد الوعاء الناقل الى اسفل ليفتح بالفتحة الذكرية على منشأ الزائدتان الصدريتان الثامنتان. وأوضحت الدراسة الهستولوجية أن الخصية تتكون من مجموعة من الجيوب التي تتم فيها مراحل تكون المنى. وتمر خلايا الطلائع المنوية فى الأنبيبات إلى أن تصبح حيوانات منوية ناضجة. تتجمع فى تكوينات عصبية الشكل يفرزها جدار الوعاء الناقل تسمى حاملات المنى. يتكون جدار الأنبيبات المجمع من طبقة من خلايا مكعبة. ينقسم جدار الوعاء الناقل إلى منطقتين، مفرزة وقاذفة الأولى تبطنها خلايا عمودية بسيطة وتحيط بها طبقة من عضلات الدائرية، بينما الثانية الجدار العضلي مكونة من العضلات طولية ودائرية و تبطنه طبقة واحدة من خلايا عمودية مهدبة.